

## Report on Travelling Fellowship to Europe undertaken by Samantha Vellei

### BACKGROUND

Over the last years the hospital clinic's group, in Barcelona headed by Professor Antonio Lacy have pioneered the development of a new approach to rectal cancer called Transanal TME.

The feasibility and safety of Natural Orifice Transluminal Endoscopic Surgery (NOTES) transanal endoscopic rectosigmoid resection using transanal endoscopic microsurgery (TEM) was previously demonstrated in human cadavers and a porcine survival model.

Since 2010 they reported the first clinical case of a NOTES transanal resection for rectal cancer using TEM and laparoscopic assistance, performed by a team of surgeons from Barcelona and Boston with extensive experience with NOTES and minimally invasive approaches to colorectal diseases<sup>i</sup>.

In 2013 they published a study demonstrated that transanal NOTES with minilaparoscopic assistance<sup>ii</sup> in the hands of a specialized team is safe; meets the oncologic requirements for high-quality rectal cancer surgery; and may offer advantages over pure laparoscopic approaches for visualizing and dissecting out the distal mesorectum. Minilaparoscopic assistance allows one to compensate for the limitations of current NOTES instrumentation to ensure the safety and adequacy of oncologic resection in these difficult cases. Careful patient selection, a specialized team, and long-term outcomes evaluation are critical before this procedure can be considered for routine clinical use.

The COLOR III TRIAL<sup>iii</sup> aimed to compare the operative and oncologic results of transanal total mesorectum excision (Ta-TME) ("down-to-up") vs. laparoscopic TME (L-TME, "up-to-down") for low rectal cancer. Additionally, a systematic review of the literature was performed to assess the quality of the current body of evidence on Ta-TME.

The difference in involvement of CRM between the two treatment strategies is thought to be in favour of the TaTME. TaTME is therefore expected to be superior to laparoscopic TME in terms of oncological outcomes in case of mid and low rectal carcinomas.

In 2014 Dr Lacy's group published a paper to compare short-term results obtained with transanal total mesorectal excision (TME) and laparoscopic surgery and the evaluation of short-term outcomes demonstrated that transanal TME is a feasible and safe technique associated with a shorter surgical time and a lower early readmission rate<sup>iv</sup>.

### HOSPITAL CLINIC

Clinical and Provincial Hospital of Barcelona (in Catalan: Hospital Clínic i Provincial de Barcelona) is a teaching hospital associated with the University of Barcelona and in particular with the Faculty of Medicine, which surrounds physically. It is located in the Eixample of Barcelona. It was founded in 1906 and is now part of the Network of Public Use Hospitals of Catalonia (PHN).

It has been awarded by IASIST in ten consecutive years as hospital TOP 20 nationally, it is one of

the four major hospitals in national and regional reference in Spain.

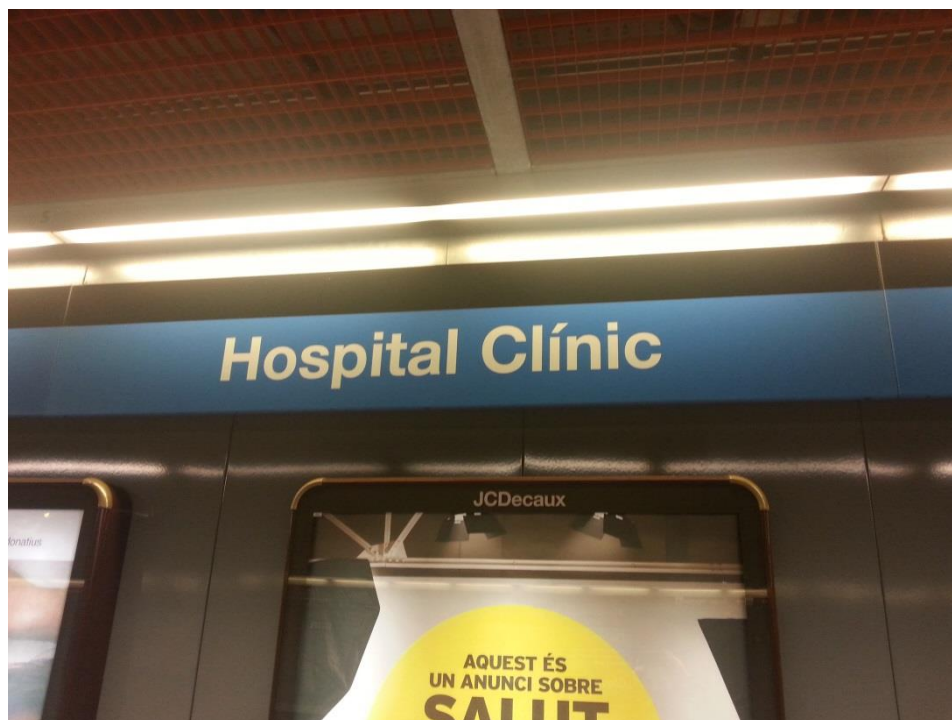
The population assigned as a community hospital, with Plató Sacred Heart Hospital and Clinic, is 540,000 inhabitants. While it is a tertiary hospital of high complexity, developing business lines for patients, not only in Catalonia but also in Spain and even internationally.

The Barnaclínic, linked to the health center Hospital, entity develops welfare activities for private patients.

Hospital Clínic de Barcelona has a long tradition of research being an institution of international reference. The Institute for Biomedical Research August Pi i Sunyer (IDIBAPS) is responsible for most of the scientific production. The management and administration of research projects are carried out through the Clinic Foundation for Biomedical Research (FCRB).

Research produced 1.005 Original articles in international journals with a total impact factor 5.595, the average impact factor is 5,567.

It is a hospital with two locations: Villarroel and Maternitat. The Villarroel headquarters are located in the Eixample district, at # 170 Villarroel Barcelona. The building is shaped like a "U" and inside is the Faculty of Medicine of the University of Barcelona, with which it forms a functional unit. In its surroundings there are a dozen bus lines. It can also be reached via the Barcelona Metro line 5.



The hospital is part of the Faculty of Medicine. Of the original complex remains relatively intact only the central body of the facade of the street Casanova, formed by a columned portico topped by a pediment with allegorical motifs in relief.



## SURGICAL DEPARTMENT STRUCTURE

The The Clínic Institute of Digestive and Metabolic Diseases (ICMDM) is composed by three surgical groups: Gastrointestinal surgery, General and Digestive Surgery (hepatic-pancreatic and Endocrine disease).

Gastrointestinal group is headed by doctor Antonio Lacy and it consist of twelve surgeons and six residents. The ward is formed from 30 to 50 beds, it's depends on weekly surgical activity.

These surgeons dealing with upper GI, lower GI surgery, bariatric surgery and Emergency, in fact the on call night duty are divided among all specialties surgeons.

The daily activities consist in : meetings, ward round, two Theatre rooms, outpatient clinics and research projects.

## MY FELLOWSHP EXPERIENCE

My fellowship started on the 8th of February.

On the first day when I arrived in the hospital Dr Lacy's secretary welcomed me and gave me a white coat, a name plate, a locker, WIFI pass, the insurance and the hospital's map.




After that I was accompanied to the room where a group of surgeons from around the world were following the taTME course. For instance the course was very important to focused main points from literature, anatomy landmarks and instructions step by step for taTME technique.

Then we saw two cases of taTME intervention performed by two teams, abdominal and perineal. This is the “Cecil approach”.

Dr. Lacy is very fond of this technique’s name and he explained us it was in honor of the lion killed on July 2015 in Zimbabwe.

In my daily schedule the work day usually starts on 8:00 with a meeting in the small doctor’s room, attended by all components of the gastrointestinal group.



Residents made a summary of patients' conditions and there were discussions on complex cases. Then the ward round started. Two groups, formed by one or two consultants and residents visited patients, followed by a nurse.

In the ward there are little rooms en-suite with two patients each.

Surgery starts about at 9:30 a.m and it finish around 3 p.m. When surgeons arrive in theatre they scrub, make surgical field and intervention starts. The nurses group is well trained in gastrointestinal laparoscopic surgery and they always know what to do.

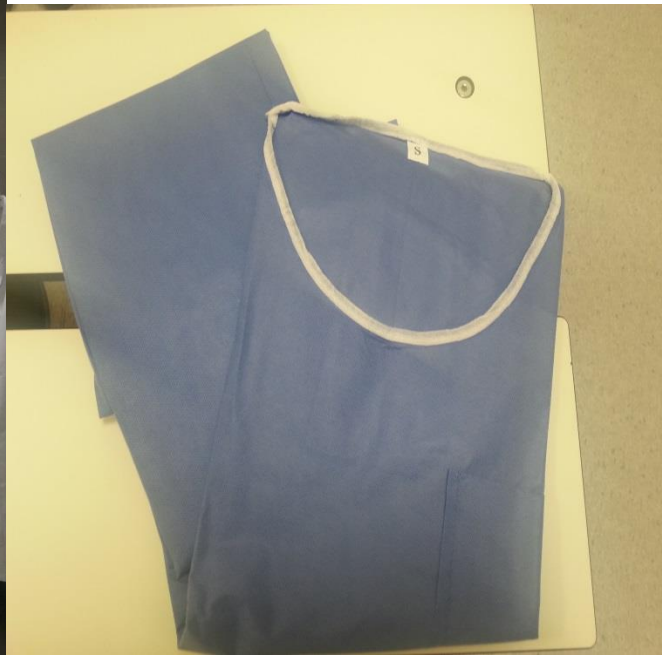Theatre activity usually consist in two theatre-lists with two cases each, every day from Monday to Friday. Interventions are performed by two consultants and one resident.

Dr. Díaz	Dr. Espert
<p>DELIAE 15/02/2018 (PNUB)</p> <p>Curs Olympus Iberia taTME</p> <p>ANA M BARRERA NORIEGA (2-4502) IMC 37 Bravo RGE Corcelles, Ibarzabal, Residente.</p> <p>RIOL CARBAJO JOSEFA (M, 81) (4516) N. Recto 3D 2C. Lacy, Delgado, Fernández, Bravo, residente.</p> <p>ANDREU DIEZ MARIA (M, 58) (3032665) N. Colon Transverso. Bravo, Jiménez, residente.</p> <p>SU. HELZEN (39) NHC 4051273 RIVERTILES Bravo, Marta</p>	<p>DELIAE 15/02/2018 (PNUB)</p> <p>Curs Olympus Iberia taTME</p> <p>REQUE'S GARCIA M SOLIDAD (M, 89) (330130) N. Recto 3D 2C Lacy, Delgado, Fernández, Bravo, residente.</p> <p>EMMA BASAGAÑA CARELL NHC 4513699 OM IMC 42</p>
<p>DELIAE 17/02/2018 (PNUB)</p> <p>DELIAE</p> <p>VIVES ALSINA TERESA (M, 71) (4597687) N. Sigma (Dx/Vinc) / Jimenez</p> <p>SANCHEZ MARTINEZ M SOCORRO (M, 74) (70388376) Rectaldiva Jr Colon Fernandez.</p> <p>Q412</p> <p>TAMAYO BORRAS ENRIQUE (M, 54) (139227) N. Recto (Miles) Jimenez</p> <p>ESPERANZA TIRADO GONZALEZ (70026511) IMC 48. OM</p>	<p>DELIAE 17/02/2018 (PNUB)</p> <p>FUENTES MARTINEZ JOSE (M, 88) (4495270) N. Gastrica. Mombian.</p> <p>Q412</p> <p>JORDI GARCIA PLANICI (70132054) IMC 58. OM / Sleeve.</p> <p>CASTRO RODRIGUEZ IRENE (M, 62) (522962) N. Colon. Corcelles, Almagro, residente.</p>
<p>DELIAE 18/02/2018 (PNUB)</p> <p>MARTINEZ GUERAU DE ARELLANO CRISTOBAL (H, 57) (70028142) ImH. Duodeno / Delgado, Otero, residente.</p> <p>PRADO SUAREZ M CARMEN (M, 71) (70693366) N. Angulo Esplénico. Mombian, Diaz del Gobo, residente.</p>	

Theatres are very well furnished for laparoscopic and robotic surgery.

Changing rooms are equipped with machines where doctors and nurses can take their uniforms by inserting the identification card.





On Tuesday at 8:00 there is teaching session. One presentation was given by residents on surgical topics with literature review, case presentation and after that there is an audience discussion moderate by a consultant.



On Thursday in the afternoon Multidisciplinary oncological meeting takes place. It is usually attended by surgeons, radiologists, oncologists and pathologists, but only the complex oncological cases are discussed.

Each consultant has one outpatient clinic a week and one resident help in this activity.

Dr Lacy let me participate to “New Approach for Rectal Diseases. Transanal Total Mesorectal Excision” course with cadavers lab, two times, in English and in Spanish languages.

I was allowed to attend all activities so I could understand Spanish way to work, to detect similarities and differences from my experience and to gain maximal exposure to an intense surgical activity in my field of interest.

Spanish was the only language spoken and my basic knowledge in Spanish were not enough to be involved in cases discussions but everyone in surgical team speaks English so it was easy to make questions and to have exhaustive answers.

I met three other fellow : a canadian, a chilean and a spanish surgeon. We had the opportunity to speak about our experience of working in foreign national healthcare systems and about our present and future projects.

## CONCLUSIONS

I had the opportunity to meet personally internationally recognized surgeons with extensive experience in colorectal surgery. I could discuss with young surgeons, very dedicated to their work, details of peri-operative management and approach about rectal cancer disease, I was able to be daily exposed to colorectal surgery and taTME technique performed by the TaTME father and to attend courses wished for surgeons from around the world to be trained in this technique. I'm grown up personally and professionally and I get out the best from this experience abroad. I know that traveling and working with different teams represents the most exciting way to learn. For this reason, I'm grateful to ACPGBI to allow me to spend a period in an internationally renowned hospital and to be trained in taTME. ACPGBI gave me the opportunity to bring this Surgery in my daily activity. My aim is always to offer the best standard of healthcare to my patients and ACPGBI helped me to reached this goal.

---

<sup>i</sup> NOTES transanal rectal cancer resection using transanal endoscopic microsurgery and laparoscopic assistance. Sylla P1, Rattner DW, Delgado S, Lacy AM. [Surg Endosc](#). 2010 May;24(5):1205-10

<sup>ii</sup> Transanal natural orifice transluminal endoscopic surgery (NOTES) rectal resection: "down-to-up" total mesorectal excision (TME)--short-term outcomes in the first 20 cases. de Lacy AM1, Rattner DW, Adelsdorfer C, Tasende MM, Fernández M, Delgado S, Sylla P, Martínez-Palli G [Surg Endosc](#). 2013 Sep;27(9):3165-72.

<sup>iii</sup> Deijen CL, Velthuis S, Tsai A, Mavroveli S, de Lange-de Klerk ES, Sietses C, Tuynman JB, Lacy AM, Hanna GB, Bonjer HJ. COLOR III: a multicentre randomised clinical trial comparing transanal TME versus laparoscopic TME for mid and low rectal cancer. [Surg Endosc](#). 2015 Nov 4. [Epub ahead of print]

<sup>iv</sup> Mar'ia Fern'andez-Hevia,, Salvadora Delgado, Antoni Castells, Marta Tasende, Dulce Momblan, MD, Gabriel D'iaz del Gobbo, Borja DeLacy, Jaume Balust, and Antonio M. Lacy. Transanal Total Mesorectal Excision in Rectal Cancer Short-term Outcomes in Comparison With Laparoscopic Surgery. [Ann Surg](#) 2014;00:1-7